

BIOCHEMICAL AND HISTOLOGICAL CHANGES INDUCED BY LOW DOSE OF CARBENDAZIM ON TESTIS OF MALE ALBINO RAT

V. Muthuviveganandave¹, P. Muthuraman², InHo Hwang² and K. Srikumar³

¹Department of Zoology, Tagore Arts College, Lawspet, Puducherry-8, India.

²Department of Animal Resource and Biotechnology, Chonbuk National University, Jeonju, South Korea.

³Department of Biochemistry and Molecular Biology, Pondicherry University, Puducherry-14, India

*Corresponding Author Email: frenzram@gmail.com

BIOLOGICAL SCIENCES

RESEARCH ARTICLE

RECEIVED ON 21-11-2011

ACCEPTED ON 03-11-2011

ABSTRACT

Carbendazim is a systemic fungicide and recently using as an anticancer drug. It was dissolved in alcohol and given to male albino rats by intradermally of 50 mM dose of each individual group at 6hr, 12hr and 24hr post effects. The animals were sacrificed after respective duration. Biochemical and histopathology studies were observed in testis. Biochemical effects on ACP, ALP, AST, ALT, GGT, Amylase and Hexokinase specific activities were significantly decreased at 6hr duration, while increased at 12hr and 24hr durations. Whereas, AST was not increased significantly in treated testis than control testis at 12hr and 24hr duration. Total protein content was significantly decreased at 12hr and 24hr. Histology changes were observed at 50mM dose level at all durations. Testis showed hypertrophy of seminiferous tubules and its cells (sclerosis). Therefore low dose of carbendazim induced testicular changes in biochemical and histologically tacks place in albino rat.

KEYWORDS: Carbendazim; testis; rat; enzyme; histological.

INTRODUCTION

Pollutants in the environment are causing various health hazards directly on living organisms. Most environmental pollution is due to pesticides. Carbendazim, a broad spectrum benzimidazole carbamate fungicide with systemic activity and it is used against various range of fungal disease of field crops, fruits, ornamentals and vegetables. On the other hand, carbendazim was proved to have toxic effects in a variety of experimental animals. It was reported that in human granulosa cells, carbendazim acted antimitotic effect by interfering with microtubules and centrosome organization during mitosis (1). Dietary administration of carbendazim for upto 90days produced slight effects on liver weight in female rats exposed to 360mg/kg per day (WHO / IPCS – 1993). Carbendazim induced haematological, biochemical and histopathological changes in liver and kidney of male rats (2). Carbendazim is used widely to prevent and control plant diseases caused by fungi.

MATERIALS AND METHODS

Materials

a) PESTICIDE: Carbendazim (98.3%), was obtained from Gharda Chemicals Ltd. Mumbai.

b) ANIMALS: Adult male albino wistar strain (10 weeks old) rats weighing 180-190g obtained from the Jawaharlal Nehru Institute of Postgraduate Medical Education and Research, Puducherry, were used in the present investigation.

c) CHEMICALS: All the chemicals and reagents used in this study were of Analytical grade.

Methods

Experimental animals were divided into 6, 12 and 24hr control and carbendazim (50mM) treated groups. Each group consisted of six animals each. Ethanol was used for Control groups. After the respective experimental period all the rats were anesthetized with anesthetic ether. Testis was removed and immediately processed for biochemical analysis. It was washed in ice cold 1.15% KCl and homogenized in a Potter-Elvehjem Teflon-glass homogenizer maintained in an ice bath. The homogenate was centrifuged at 10,000 x g in a Sorvall RC-5C refrigerated centrifuge for

30minutes and the supernatant was removed and used for it further investigations. Alanine aminotransferase (ALT) and aspartate aminotransferase (AST) enzyme activities measured by the method of Reitman and Frankel (3), alkaline phosphatase (ALP) enzyme activity (4), measurement of acid phosphatase activity (ACP) (5), gamma glutamyltranspeptidase (GGT) activity (6), amylase activity (7) and hexokinase enzyme activity was measured by the method of Mc Lean and Brown (8). The data obtained were analyzed by paired t-test between control and treatments. $P < 0.05$ and $P < 0.01$ were considered to be significant. Animal testis tissue was removed surgically after 6hr, 12hr and 24hr from respective 50mM Carbendazim treatment groups. The removed testis was kept in 10% formalin and processed by the paraffin technique. The sections were taken of 5 μ thickness and mounted on slides and stained with hematoxylin and eosin. The stained sections were morphologically evaluated under compound microscope.

Statistical analysis

All the values were expressed as mean \pm SEM. Statistical analysis was done using SPSS 11. The statistical significance of differences between the means was assessed by paired t-test. A difference at $P < 0.05$ was considered statistically significant.

RESULT AND DISCUSSION

Treatment of rats with carbendazim produced significant changes in biochemical parameters as well as in cellular architecture. The results of biochemical analysis of rats in control and treated groups are given in Table 1. GGT enzyme activity is reduced 17.1% at 6 hr whereas 14.5 and 6.1% elevated at 12 and 24 hrs respectively. Amylase enzyme activity is reduced 24.4% at hr whereas 286 and 205.5% significant elevation found at 12 and 24 hrs respectively. Hexokinase enzyme activity is reduced 16.3% at 6 hr while 23.6 and 27% significant enhancement found at 12 and 24 hr respectively. ACP enzyme activity was reduced 80.1% at 6 hr whereas 121 and 55.2% significant elevation found at 12 and 24 hrs respectively. ALP enzyme activity was reduced 8.8% at 6 hr whereas

26.4 and 49% elevation found at 12 and 24 hrs respectively.

Treatments of rats with carbendazim produced significant changes AST, ALT enzyme activity and total protein content at 6, 12 and 24 hrs. AST enzyme activity is reduced 14% at 6 hr while 2 and 15% mild elevation found at 12 and 24 hrs. ALT enzyme activity is reduced 57.1% at 6 hr whereas 73.3 and 49.5% elevation found at 12 and 24 hrs respectively. Total protein content is significantly elevated at 42.8% at hr whereas protein content is reduced significantly 60 and 50% at 12 and 24 hrs respectively. The histological studies were showed to changes of ultrastructurally in the testis at 6, 12 and 24hrs post treatment of Carbendazim. Treatments of rats with carbendazim produced significant changes in cellular architecture. At 6 hr, mild hypertrophy was found in seminiferous tubule whereas sclerosis was occurred at 12 and 24 hrs (Figure 1, Table 1)

Animals including human may be exposed to carbendazim through consumption of food derivatives. Primary exposure for the general animals will be from residues of benomyl and carbendazim on food crops (9). There is limited research about the effects of carbendazim and benomyl on testis and biochemical and histological parameters in mammals. Therefore, in the present study, the effect of carbendazim on the biochemical parameters in male rat testis was evaluated. Increased GGT activity suggesting that elevated transpeptidases that does not auger well for tissues. Increased HK activity leads to greater glucose utilization for energy yield in the cells. Increased HK activity was indicative of greater phosphorylation in the cells of the various rat tissues. HK increase in blood, glucose level in the rat possibility making the animal hypoglycemic in due course.

Figure 1: Section of rat testis showing, normal architecture (control), mild hypertrophy of the cells of seminiferous tubule (CAR-6 hr) and sclerosis (CAR-12 hr and CAR-24 hr) following administration of Carbendazim (50mM)

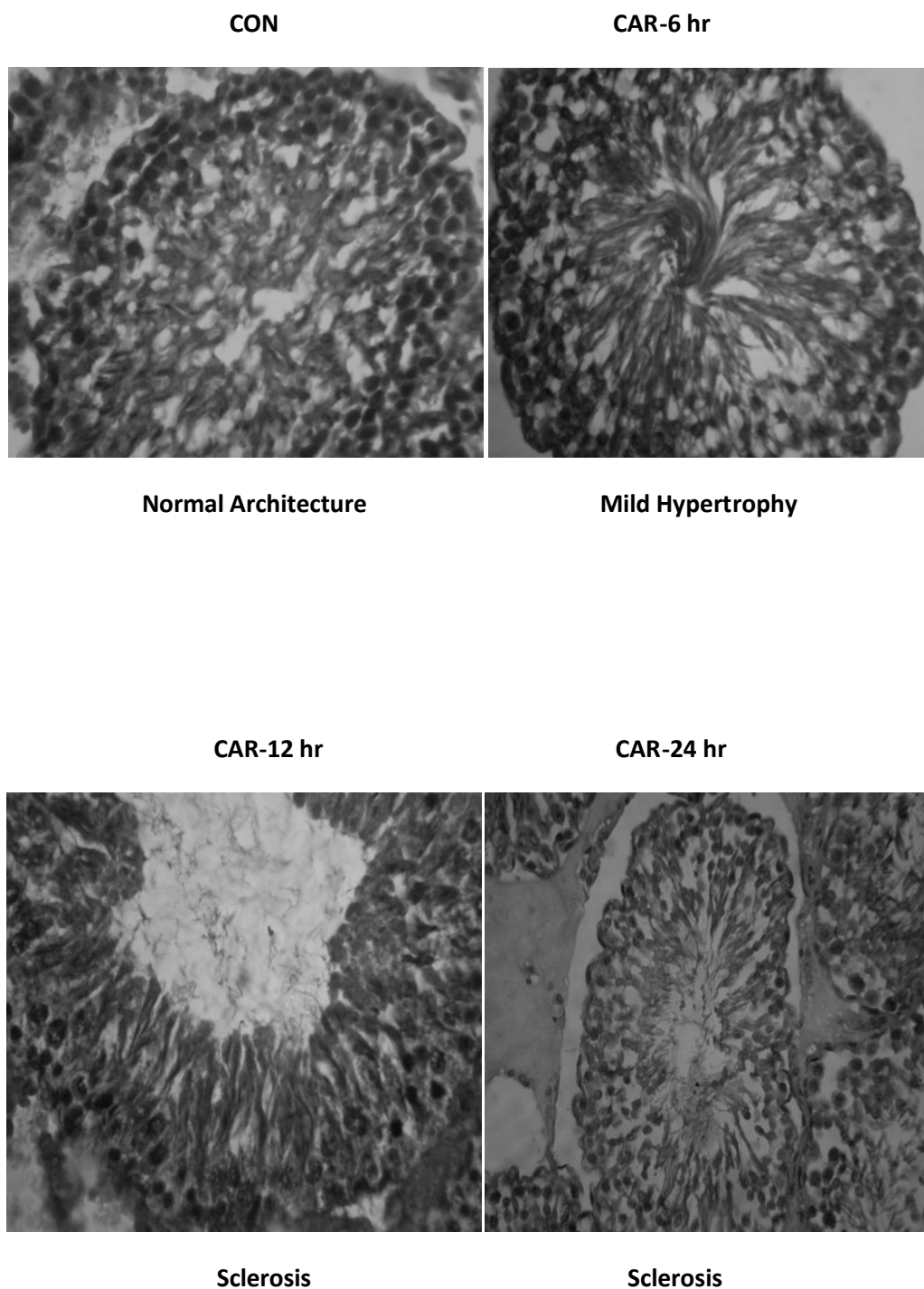


Table1: Rat Testicular Selective Enzymes specific activity (IU/mg protein/g x10⁻²) and Total protein (mg/g) of albino rat control and treated with 50mM CAR (Carbendazim) at 6, 12 & 24 hr duration.

PARAMETERS	EXPRIMENT	6 hr	12 hr	24 hr
GGT	CONTROL	1.75 ± 0.272	2.90 ± 0.141	2.44 ± 0.052
	TREATMENT	1.45 ± 0.181**	3.32 ± 0.166**	2.59 ± 0.034**
Amylase	CONTROL	0.119 ± 0.018	0.043 ± 0.006	0.072 ± 0.007
	TREATMENT	0.090 ± 0.012**	0.166 ± 0.022**	0.220 ± 0.021**
Hexokinase	CONTROL	1.53 ± 0.135	1.65 ± 0.127	1.48 ± 0.127
	TREATMENT	1.28 ± 0.112**	2.04 ± 0.103**	1.88 ± 0.103**
ACP	CONTROL	12.39 ± 0.469	12.92 ± 0.948	13.79 ± 1.14
	TREATMENT	2.46 ± 0.031**	28.55 ± 0.785**	21.4 ± 1.05**
ALP	CONTROL	17.00 ± 1.44	18.32 ± 1.54	9.33 ± 0.733
	TREATMENT	15.51 ± 1.27	23.16 ± 1.28*	13.90 ± 0.986**
AST	CONTROL	17.18 ± 0.748	17.58 ± 0.856	12.14 ± 0.581
	TREATMENT	14.79 ± 0.681**	17.93 ± 1.258	13.94 ± 1.17
ALT	CONTROL	4.48 ± 0.241	6.00 ± 0.473	3.88 ± 0.312
	TREATMENT	1.92 ± 0.276**	10.4 ± 0.537**	5.80 ± 0.335**
PROTEIN	CONTROL	70.0 ± 2.84	75.0 ± 2.92	80.0 ± 3.83
	TREATMENT	100 ± 3.53	30.0 ± 1.94**	40.0 ± 2.35**

Values are expressed mean ± SEM from 6 rats in each group. Statistical significant at p≤0.05 = * and p≤0.01 = **.

ACP increase in rat tissues confirmed the increase in the dephosphorylation potential within the rat cell, which leads to reduction in stored phosphate. The phosphate depletion affecting the calcium: phosphorous ratio within each cell, eventually in membrane damage and lack of energy compounds. Tissue AST increase is indicative of an augmented process of oxalic acetate formation from aspartate. Decreased AST indicate the reduced transamination. Decrease in ALP indicates reduced dephosphorylation and increased in ALP activity

suggest the enhanced dephosphorylation of organic substances and affect the signal transduction events. Increased ALT activity was observed that signified increased transamination reaction within the cells. Decreased ALT was indicating the reduced transamination process. AST and ALT enzyme activities level increased significantly in rats treated with 520, 560 and 600 mg/kg benomyl for 7 days. However, serum ALP levels increased slightly at the same doses (10). The difference in the results may be attributed to

the exposure time and the main pesticide. From the present study it is observed that even low dose of carbendazim may have some adverse effect on the testis by altering the biochemical and histological changes. This may have an impact on the reproductive function of the organism.

ACKNOWLEDGMENT

The authors gratefully acknowledge the financial support received as grants from the Department of Science and Technology (SR/SO/AS-16/2004 and DST-FIST), funding agency, India. It should be acknowledged that this work was, partly, supported by a grant from the Next-Generation BioGreen 21 Program (No. PJ008191), Rural Development Administration, Republic of Korea.

REFERENCES

1. Can, A. and Albertini, D.F. Stage- specific effects of carbendazim on meiotic cell cycle progression in mouse oocytes. *Mol. Reprod. Dev.*, 46:351-362, (1997)
2. Selmanoglu, G., Barlas, N., Songur, S. and E. A. KocSkaya. Carbendazim induced haematological, biochemical and histopathological changes to the liver and kidney of male rats. *Hum. Exp. Toxicol.*, 20:625-630, (2001)
3. Reitman, S. and Frankel, S. A Colorimetric method for the determination of serum glutamic oxaloacetate and glutamic pyruvic transaminases. *Amer.J.Clin.Path.*, 28:5663, (1957).
4. Bessey, O.A., Lowry, O.H., Brock, N.J. A Method for the determination of alkaline phosphatase. *J. Biol. Chem.*, 164:321-329, (1946).
5. Tennis Wood, M., Biri, C.E. and Clark, A.F. Acid phosphatase androgen dependant markers of rat prostate. *Can. J. Biochem.*, 54:350, (1976)
6. Volohonsky, G., Tuby, C.N.Y.H., Porat, N., Wellman-Rousseau, M. A spectrophotometric assay of gamma-glutamylcysteine synthetase and glutathione synthetase in crude extracts from tissues and cultured mammalian cells, *Chem. Biol. Interact.*, 140:49-65, (2002)
7. Bernfeld, P. Amylases alpha and beta. *Meth. Enzymol.*, 149, (1955)
8. Mc Lean and Brown. Some Properties of Rat-Liver Glucose-Adenosine Triphosphate Phosphotransferases. *Biochem. J.*, 100:793, (1966)
9. WHO/IPCS. Carbendazim. *Environ. Health Criter. Monogr.*, 149:1-17, (1993)
10. Igbedioh SO, Akinyele IO. Organ enlargement and liver function in benomyl fed rats. *Discovery Innovation*. 8: 241–247, (1996).



* Corresponding Author

Prof. K. Srikumar
Dept. of Biochemistry and Molecular Biology,
Pondicherry University, Puducherry-14, India