



Risk Factors Associated with Intravenous Bisphosphonate Induced Osteonecrosis of Jaw in Cancer Patients – A Systematic Review

Koushika Mohan¹, Sindhu R², Dinesh Dhamodhar⁴, Sathiyapriya S², Prabu D^{3*}, Rajmohan M⁴ and Bharathwaj V V²

¹Undergraduate Student, ²Senior Lecturer, ³Professor and Head of the Department, ⁴Reader, Department of Public Health Dentistry, SRM Dental College, Ramapuram, Chennai, India.

Received: 04 Jul 2022/ Accepted: 12 Aug 2022 / Published online: 3 Dec 2022

*Corresponding Author Email: researchphdsrm@gmail.com

Abstract

BACKGROUND: Osteonecrosis of jaw is a pathological condition of maxilla and mandible which is prevalent in society for many years. In past few years, there was recurrence of this condition in those who were not treated with radiation. A connection was found between osteonecrosis of jaw and bisphosphonates. **AIM:** To find out the risk factors that are mainly related to osteonecrosis of jaws that is caused by intravenous bisphosphonates in cancer patients. **METHODS:** A literature search was done using PubMed, ResearchGate, Lilacs, Cochrane, Science direct using the terms – Osteonecrosis of jaws, Intravenous bisphosphonate therapy, Cancer. 190 articles were screened from which 14 were full text articles that were assessed for eligibility and 7 articles were considered for qualitative analysis. **RESULTS:** The risk factors that are related to bisphosphonate induced osteonecrosis of jaws are age, poor oral hygiene, ill-fitting dentures, obesity, smoking, dental extraction. **CONCLUSION:** Bisphosphonates related osteonecrosis of jaws can be prevented by following appropriate oral hygiene.

Keywords

Cancer, Intravenous bisphosphonates, osteonecrosis of jaws

INTRODUCTION:

Osteonecrosis of jaw is a pathological condition of maxilla and mandible which is prevalent in society for many years. There is loss of cellular elements of bone and damage to blood vessels that leads to low supply of blood to the bone. Any trauma due to frequent dental procedures, infections, chemotherapy, cancer, disorders of coagulation, arthritis, usage of corticosteroids, osteoporosis, sickle cell disease, systemic lupus erythematosus, Gaucher's disease pose as a risk factors.[1]

Non vital necrosed bone is seen in oral cavity. Osteonecrosis of jaw was mostly seen in head and neck associated cancer patients who were given radiation.[2] In past few years, there was recurrence of this condition in those who were not treated with radiation. A connection was found between osteonecrosis of jaw and bisphosphonates. [3] Bisphosphonates are synthetic compounds of pyrophosphate. They get collected in the areas where there is active formation of bone. Due to this, the areas are mostly unaffected by osteoclast.

Various types of bisphosphonates are in use for treating cancer. [4]

Bisphosphonates are divided into two different groups. First group has etidronate and clodronate. This group consist of a carbon atom at center to which a side chain is connected. The second group has pamidronate, alendronate, ibandronate. This group of bisphosphonates have a nitrogen atom connected to them. The second group of bisphosphonates are more effective than the first group. [5]

Bisphosphonates have the tendency to cause renal dysfunction. If they are not absorbed by the bone, they are excreted out by kidneys without being metabolized. The risk of renal dysfunction might be increased in case zoledronate compared to other bisphosphonates. Gastrointestinal tract is usually affected if bisphosphonates are taken orally. Mucosal inflammation, diarrhea, bloating is frequent. Ulcerations and inflammation in esophagus are dangerous side effect of alendronate and risedronate. Other side effects like pain in muscle and bone, slightly increased body temperature, high white blood cell count was noted. Osteonecrosis of jaw due to bisphosphonates was first reported in the year of 2003. Most of the cases were related to usage of risedronate, alendronate, pamidronate, zoledronate, ibandronate. Till today not a single case has been reported with the usage of clodronate. The presence of osteonecrosis of jaw caused by bisphosphonates in individuals with cancer like breast cancer, prostate cancer and multiple myeloma ranges between 1% to 10%. Durie et al gave an account of osteonecrosis of jaw in 10% of individuals with multiple myeloma who were given zoledronate and 4% of individuals who were given pamidronate. Most of the cancer patients already had diseases associated with gingiva and jaw bone that gave a pathway for entry of pathogens. [6]

Bisphosphonates have detrimental effects on bone cells and soft tissues. Vigorous resorption is seen in bone in osteonecrosis of jaw. Infection might play a key role in development of this condition.[7]

The areas of metabolic activity of skeletal muscle will be reduced due to frequent using of bisphosphonates. This leads to low binding of bisphosphonates to skeletal exposing monocytes and macrophages to bisphosphonates for longer period of time. This can cause several dangerous defects. Osteonecrosis of jaw due to bisphosphonates can prevented by stopping the medication or by managing vitamin D deficiency. Patients having bone cancer and osteoporosis vitamin D supplements are necessary. The rate of healing of oral mucosa can be increased by giving monocyte colony stimulating

factor or monocyte – macrophage colony - stimulating factor. Unwanted increase in count of osteoclast will not have any negative effects in individuals with cancer because of bisphosphonates which are already absorbed by the bones. In patients with osteoporosis but without cancer parathyroid hormone is administered so that osteonecrosis of jaw is treated. [8]

Sequestrectomy and debridement was mostly used therapy. Bone surgery was performed with a motive to remove necrosed bone but bone defects started to develop. Conservative osteoplasty was done to reduce ulcerations of soft tissues. Necrosed area was protected by vinyl splints to reduce trauma. Pain and secondary infections should be controlled by administering antibiotics. [9]

AIM:

To find out the risk factors that are mainly related to osteonecrosis of jaws that is caused by intravenous bisphosphonates in cancer patients.

MATERIALS AND METHODOLOGY:

STUDY DESIGN: Systematic review of randomized control trials.

ELIGIBILITY CRITERIA:

Inclusion criteria

- Original articles
- Full text articles

Exclusion criteria

- Non randomized studies
- Articles without full text

SEARCH STRATEGY

Literature published on intravenous bisphosphonates induced osteonecrosis of jaw which includes articles in database such as PubMed, Science Direct, Wiley, Cochrane were taken into study for review.

SEARCH ENGINE:

- PubMed
- Science Direct
- Cochrane
- Wiley
- Research Gate

RESULTS:

190 articles were screened from which 14 were full text articles that were assessed for eligibility and 7 articles were considered for qualitative analysis. **Figure 1** shows flow diagram of reports that were identified, duplicates removed, screened, excluded, assessed for eligibility and included in the systematic review.

Table 1 shows the characteristics of the intervention in the included studies. All 7 studies differed

individually in sample size, age of population and the duration of intervention. All the seven trials were performed on cancer patients.

Table 2 shows outcome of data of intravenous bisphosphonate induced osteonecrosis of jaw in the

included studies. **Table 3** shows the bias assessment of the included studies.

Table 3 shows bias assessment of included studies.

FIGURE 1

Flow diagram showing the number of studies identified, screened, assessed for eligibility, excluded and included in the systematic review

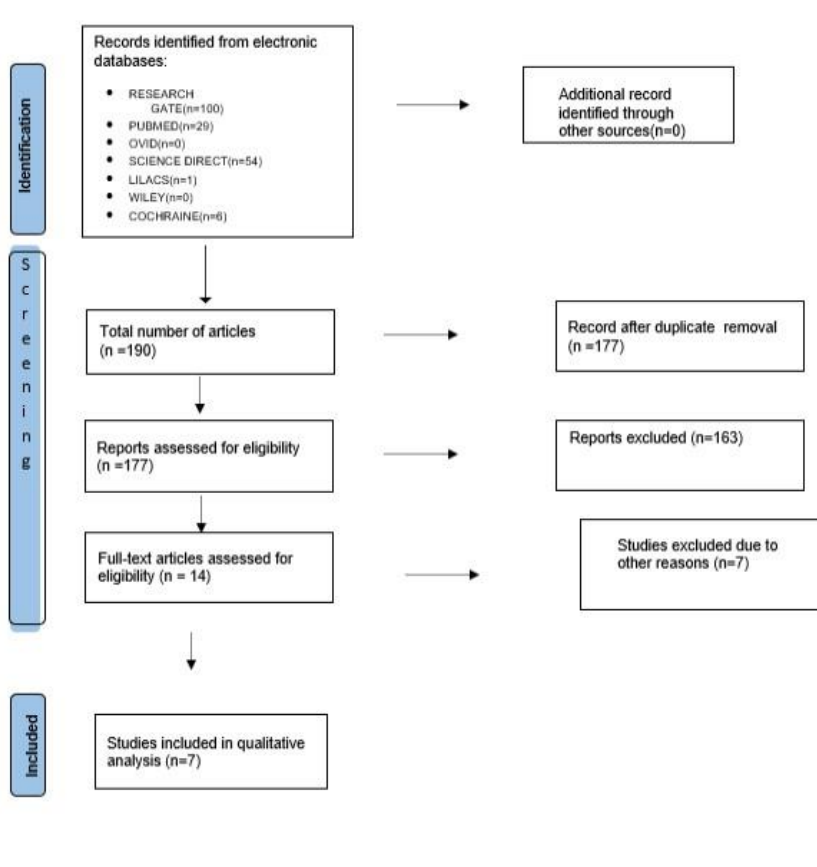


TABLE 1: CHARACTERISTICS OF THE INTERVENTIONS IN THE INCLUDED STUDIES

| AUTHOR NAME | YEAR | SAMPLE SIZE | DURATION | PATIENT CHARACTERISTICS | INTERVENTIONS (TYPE OF BISPSPHONATE USED) |
|--------------------------------------|-------------|--------------------|-----------------|---|---|
| Cherry L. Estilo et al. [10] | 2008 | 310 | 2 years | Patients who were having cancer and receiving intravenous bisphosphonate therapy | Pamidronate, Zoledronic acid, Pamidronate and Zoledronic acid |
| Konstantinos vahtsevanos et al. [11] | 2009 | 1621 | 1 year | Patients of age between 41-92 years who had cancer and were receiving intravenous bisphosphonate therapy | Pamidronate, Zoledronate, Ibandronate |
| Zaid H Baqain et al. [12] | 2010 | 41 | 3 years | 25 women and 16 men aged between 29-88 years who were willing to participate and those who were receiving intravenous bisphosphonate therapy | Zoledronate, Zoledronate and Alendronate, Pamidronate |
| Serkan Agacayak et al. [13] | 2013 | 272 | 1 year | Individuals aged between 46-53 years who were willing to participate and those who were having cancer and were being treated with bisphosphonates | Zoledronic acid, Ibandronic acid, Pamidronate |
| Marcin Kos. [15] | 2015 | 197 | 3 years | Patients aged between 48-77 years who were willing to participate and those were having cancer | Pamidronate, Zoledronate, Ibandronate |
| Carmen Vidal-Real et al. [15] | 2015 | 194 | 1 year | 55 women and 139 men of age between 42-93 years who were treated with intravenous bisphosphonate therapy | Zoledronic acid |
| Andreea elena lungu et al. [16] | 2018 | 20 | 2 years | 7 men and 13 women of age between 43-83 years had lesions in gingival mucosa and those who had cancer | Zoledronic acid, Ibandronate, Alendronate |

TABLE 2: OUTCOME DATA AS REPORTED IN INCLUDED STUDIES

| AUTHOR NAME | YEAR | EFFECT MEASURE | RESULTS |
|--------------------------------------|------|--|--|
| Cherry L. Estilo et al. [10] | 2008 | Status of osteonecrosis of jaws during the first dental checkup and during follow up | Resolution of osteonecrosis of jaws occurred in 3 patients. In these 3 patients, intravenous bisphosphonate therapy was discontinued in 1 and remain unchanged in other 2 patients. In the patient in whom therapy was discontinued complete resolution of maxillary osteonecrosis of jaw site occurred after bone lesion became mobile and exfoliated 2 years following first dental visit. In other 2 patients with ONJ resolution, the ONJ lesion resolved after 1 month in one patient (with history of 35 months of pamidronate for multiple myeloma) and after 25 months in the other (with the history of 64 months of pamidronate and zoledronic acid for bone cancer). In 8 patients the ONJ site remained stable and unchanged (range of follow up 0-27 months) while 13 had progression of ONJ (range of follow up 3-26 months). 7 patients succumbed to cancer during study period and 4 were lost to follow up. |
| Konstantinos vahtsevanos et al. [11] | 2009 | Relative risks, crude and adjusted odd ratios(aORs) cumulative hazard ratios for ONJ development | Crude ONJ incidence was 8.5%, 3.1%, 4.9% in patients with multiple myeloma, breast cancer and prostate cancer respectively. Patients with breast cancer demonstrated a reduced risk for ONJ development which turned out be nonsignificant after adjustment for other variables. Multivariate analysis demonstrated that use of dentures (aOR=2.02;95% CI, 1.03 to 3.96), history of dental extraction (aOR=32.97;95% CI, 18.02-60.31) having ever received zoledronate (aOR=28.09;95% CI, 5.74-137.43) and each zoledronate dose (aOR=2.02;95% CI,1.15-3.56) were associated with increased risk for ONJ. |
| Zaid H Baqain et al. [12] | 2010 | Intravenous bisphosphonate | Of the 41 patients who received bisphosphonate ,4 (9.7%) had bisphosphonate induced osteonecrosis of jaw; two in maxilla, one in mandible and one in maxilla and mandible. Osteonecrosis was asymptomatic in 3 cases and asymptomatic in 1 case. Two of the four cases occurred in males with prostate cancer and two in females with multiple myeloma: all were only treated by zoledronate, all had associated morbidities; two were receiving chemotherapy plus steroid, one chemotherapy and radiotherapy, and one chemotherapy steroids and smoking. The duration of treatment with bisphosphonate was longer in patients who had BRONJ compared with those who did not; however, this difference was not statistically significant. |

| | | | |
|---------------------------------|------|---|---|
| Serkan Agacayak et al. [13, 14] | 2013 | Type and duration of intravenous bisphosphonate therapy | <p>The mean age was 53.3 years (range from 14 to 82), 52.2% (142) were male and 47.8% (130) were female. 209 of 272 (76.8%) received zoledronic acid, 60 (22.1%) received ibandronic acid and 3 (1.1%) received pamidronate. 112 (41.3%) were treated for metastatic breast cancer, 102 (37.3%) for metastatic lung cancer, 32 (11.8%) metastatic prostate cancer and 26 (9.6%) for other cancer. The mean receiving time was 12.2 (1-61) months for zoledronic acid, 15.1 (1-78) months for ibandronic acid, 11 (1-20) months for pamidronate. Osteonecrosis was detected 6 of 272 (2.2%) patients.</p> |
| Marcin Kos. [15] | 2015 | Type of cancer, Duration and type of bisphosphonate, cumulative incidence and incidence rate of BRONJ | <p>The cumulative incidence of BRONJ was 9.64%. Among different types of cancer, BRONJ occurred in 10.71% (12/112) of multiple myeloma, 9.68% (6/62) of breast carcinoma and 6.67% (1/15) of other neoplasm. The incidence rate of BRONJ in the evaluated population was 1 in 28 patients per year of bisphosphonate treatment. Patients with BRONJ had experienced longer median duration of malignant disease. ($p=0.008$; Mann-Whitney rank sum test) and longer periods of bisphosphonate administration, i.e. a higher number of given doses ($p=0.001$; Mann-Whitney rank sum test). No BRONJ occurred in patients taking bisphosphonates for less than 12 given doses. The risk of BRONJ with zoledronate was 5-fold higher than that of pamidronate or ibandronate.</p> |
| Carmen Vidal-Real et al. [15] | 2015 | Intravenous bisphosphonate therapy | <p>Of the 25 patients (12.9%) who suffered ONJ 8% had degree 0, 24% degree I, 72% degree II and 8% degree III. The complications appearing in patients undergoing bisphosphonate therapy were only observed in patients that developed ONJ except for one patient who had temporary paresthesia of mental region of 4th quadrant. The most remarkable complication as pain which was reported by 80% of patient followed by bone spicules (24%) abscess (24%) and in lower degree oroantral communication (4%) and extraoral fistula (4%).</p> |
| Andreea elena lungu et al. [16] | 2018 | Treatment with bisphosphonates, lesions of mucous gingiva of maxillaries exposed necrotic bone older than 8 weeks | <p>Of 20 patients in total, 13 were women and 7 were men. All patient included in the study had lesions of gingival maxillary mucosal areas with exposure of subjacent necrotic bone. 60% of them were under intravenous treatment with zoledronic acid. A single patient was under oral treatment with bisphosphonate. 19 of these 20 patients developed osteonecrosis following a dental extraction while 1 case was due to instability of mandibular mobile prosthesis. 61% of patients included in the study developed a necrotic process</p> |

in mandibular bone. 80% of localizations were in posterior areas.

TABLE 3: BIAS ASSESSMENT AS INCLUDED IN THE STUDIES

| Author name, year | Random sequence generation | Allocation concealment | Blinding of outcome | Incomplete outcome data | Blinding of participants and personnel | Selective reporting | Judgemental Bias |
|--|----------------------------|------------------------|---------------------|-------------------------|--|---------------------|------------------|
| Cherry L. Estilo et al. [10] 2008 | + | ? | - | + | - | - | + |
| Konstantinos vahtsevans et al. [11] 2009 | - | - | - | + | - | + | ? |
| Zaid H Baqain et al. [12] 2010 | + | ? | ? | - | + | + | ? |
| Serkan Agacayak et al. [13] 2013 | - | - | ? | + | ? | + | + |
| Marcin Kos. [15] 2015 | - | - | - | + | - | + | + |
| Carmen Vidal-Real et al. [15] 2015 | - | - | - | + | - | + | + |
| Andreea elena lungu et al. [16] 2018 | - | - | - | + | - | + | + |

+ = low risk of bias; - = high risk of bias; -? = unclear risk of bias

DISCUSSION:

In patients receiving zoledronic acid the onset of osteonecrosis of jaw was short (8.7 months) compared with people receiving only pamidronate (44.5 months) or pamidronate and zoledronic acid (31.5 months).[10]

Osteonecrosis of jaws causes misery which leads to bone loss. The prevalence of osteonecrosis of jaw is between 0.94% to 18.6%. Osteonecrosis of jaw was seen in many patients having multiple myeloma than

the breast cancer. Walter et al showed the prevalence of osteonecrosis of jaws 18.6% in patients having prostate cancer who were receiving zoledronate treatment. When compared to pamidronate, Zoledronate causes osteonecrosis of jaws more. Hoff et al showed zoledronate had 15-fold higher hazard ratio. There are many complications with usage of zoledronate. So more careful and thorough follow up is done for those

patients who are being treated with zoledronate. Ibandronate and pamidronate are safer drugs. [11] The entire jaw bone is affected. The prevention of osteonecrosis of jaw is necessary. Direct injury to the bone should be avoided in cancer patients who are receiving intravenous bisphosphonate therapy mainly for those who are receiving repeatedly. Osteonecrosis of jaws maybe asymptomatic until tissues adjacent to it gets inflamed or there is any proof of infection. [12]

According to current guidelines, the treatment for bisphosphonate induced osteonecrosis of jaws should be done by qualified dental specialist. Managing the pain and infection should be the first choice. Surgical management should be conservative. Experts suggest discontinuing of bisphosphonate treatment but benefit of that is still being questioned. According to the reports of the American Society for Bone and Mineral Research (ASBMR), indications of bisphosphonates should be considered. All the necessary measures should be done to prevent osteonecrosis of jaws. So according to ASBMR and other cancer institutions, patients should be educated about advantages and disadvantages of bisphosphonates, signs, symptoms and risk factors of osteonecrosis of jaw. Patients are advised to improve oral hygiene and regular dental visits. Ripamonti et al showed prevalence of osteonecrosis of jaw was reduced by 76% if proper preventive measures were taken.[13]

Old age is a risk factor for the development of osteonecrosis of jaws. It maybe because of reduced healing and regenerative process in old age. Periodontal disease and dental caries can lead to surgery in older age. The use of dental prosthesis is also a risk factor of osteonecrosis of jaws. Many studies are required to show that the age plays a role in the development of osteonecrosis of jaws.[15]

Cortisone treatment, smoking, diabetes, obesity, chemotherapy is also risk factors of osteonecrosis of jaws. [15]

According to Woo's study, there is a time gap of 1 to 3 months between happening of risk factor and symptoms. Based on medical literature, there is a time gap of 4 to 6 months between happening of risk factor and appearance of symptoms. Based on study conducted in china among female patients having breast cancer, there was a time gap of 8.58 months between dental extraction and osteonecrosis. Ninety- five percentage of maxillary osteonecrosis was due to dental extraction. [16]

CONCLUSION:

There is rise in prevalence of osteonecrosis of jaws due to intravenously administered bisphosphonate

in cancer patients. Age, poor oral hygiene, smoking, diabetes, obesity, dental extraction and any ill-fitting dentures are the main risk related to bisphosphonate induced osteonecrosis of jaws. The prevention and treatment for osteonecrosis of jaws should be done only by qualified dental specialist. Bisphosphonate related osteonecrosis of jaws can be prevented by taking appropriate measures and educating the patients about the disease and advising them to follow proper oral hygiene to reduce the risk of osteonecrosis.

ACKNOWLEDGEMENTS: Nil

SOURCE OF FUNDING: Nil

REFERENCES:

- [1] Ruggiero S, Gralow J, Marx RE, Hoff AO, Schubert MM, Huryn JM, Toth B, Damato K, Valero V., *Practical guidelines for the prevention, diagnosis, and treatment of osteonecrosis of the jaw in patients with cancer*. Journal of oncology practice,2(1):7-14, (2006)
- [2] Khan AA, Rios LP, Sándor GK, Khan N, Peters E, Rahman MO, Clokie CM, Dore E, Dubois S., *Bisphosphonate-associated osteonecrosis of the jaw in Ontario: a survey of oral and maxillofacial surgeons*. The Journal of rheumatology, 38(7):1396-1402, (2011)
- [3] Hoff AO, Toth BB, Altundag K, Johnson MM, Warneke CL, Hu M, Nooka A, Sayegh G, Guarneri V, Desrouleaux K, Cui J., *Frequency and risk factors associated with osteonecrosis of the jaw in cancer patients treated with intravenous bisphosphonates*. Journal of Bone and Mineral Research, 23(6):826-836, (2008)
- [4] Bamias A, Kastiris E, Bamia C, Mouloupoulos LA, Melakopoulos I, Bozas G, Koutsoukou V, Gika D, Anagnostopoulos A, Papadimitriou C, Terpos E., *Osteonecrosis of the jaw in cancer after treatment with bisphosphonates: incidence and risk factors*. Journal of Clinical Oncology, 23(34):8580-8587, (2005)
- [5] Boonyapakorn T, Schirmer I, Reichart PA, Sturm I, Massenkeil G., *Bisphosphonate-induced osteonecrosis of the jaws: prospective study of 80 patients with multiple myeloma and other malignancies*. Oral oncology,44(9):857-869, (2008)
- [6] Diel IJ, Bergner R, Grötz KA., *Adverse effects of bisphosphonates: current issues*. The journal of supportive oncology,5(10):475-482, (2007)
- [7] Reid IR., *Osteonecrosis of the jaw—who gets it, and why?*. Bone,44(1):4-10, (2009)
- [8] Puzanov M., *Osteonecrosis of the jaw and the role of macrophages*. Journal of the National Cancer Institute, 103(3):232-240, (2011)
- [9] Migliorati CA, Schubert MM, Peterson DE, Seneda LM., *Bisphosphonate-associated osteonecrosis of mandibular and maxillary bone: an emerging oral*

- complication of supportive cancer therapy. *Cancer*,104(1):83-93, (2005)
- [10] Estilo CL, Van Poznak CH, Williams T, Bohle GC, Lwin PT, Zhou Q, Riedel ER, Carlson DL, Schoder H, Farooki A, Fornier M., *Osteonecrosis of the maxilla and mandible in patients with advanced cancer treated with bisphosphonate therapy*. *The oncologist*,13(8): 911-920, (2008)
- [11] Vahtsevanos K, Kyrgidis A, Verrou E, Katodritou E, Triaridis S, Andreadis CG, Boukovinas I, Koloutsos GE, Teleioudis Z, Kitikidou K, Paraskevopoulos P., *Longitudinal cohort study of risk factors in cancer patients of bisphosphonate-related osteonecrosis of the jaw*. *Journal of Clinical Oncology*,27(32):5356-5362(2009)
- [12] Baqain ZH, Sawair FA, Tamimi Z, Bsoul N, Al Edwan G, Almasad JK, Abbadi AA., *Osteonecrosis of jaws related to intravenous bisphosphonates: the experience of a Jordanian teaching hospital*. *The Annals of The Royal College of Surgeons of England*, 92(6):489-494, (2010)
- [13] Agacayak S, Inal A, Agacayak E, Atilgan S, Isikdogan A, Ucan MC, Guven S, Gunay A., *Prevalence of osteonecrosis of the jaw in cancer patients who were treated intravenous bisphosphonates*. *HealthMED*, 7(6):1807-1814, (2013).
- [14] Sathish Mohan Botsa*, Seetharam P, I. Manga Raju, Suresh P, G. Satyanarayana, Sangaraju Sambasivam, Susmitha Uppugalla, Tejeswararao D, *Nanohybrid material of Co-TiO₂ and optical performance on methylene blue dye under visible light illumination*. *Hybrid Advances*, 1:100008 (2022).
- [15] Kos M., *Incidence and risk predictors for osteonecrosis of the jaw in cancer patients treated with intravenous bisphosphonates*. *Archives of Medical Science*, 11 (2): 319–324, (2015).
- [16] Vidal-Real C, Pérez-Sayáns M, Suárez-Peñaranda JM, Gándara-Rey JM, García-García A., *Osteonecrosis of the jaws in 194 patients who have undergone intravenous bisphosphonate therapy in Spain*. *Medicina oral, patología oral y cirugía buccal*,20(3): 267-272, (2015)
- [17] Lungu AE, Lazar MA, Tonea A, Rotaru H, Roman RC, Badea ME., *Observational study of the bisphosphonate-related osteonecrosis of jaws*. *Clujul Medical*, 91(2):209-215, (2018)