



Modulatory effect of *Morinda citrifolia L.* fruit extract on Methotrexate induced hepatotoxicity evidences from histopathology and biochemistry

Bhakti A Mhatre and Thankamani Marar *

School of Biotechnology & Bioinformatics, D. Y. Patil Deemed to be University, Sector 15, CBD, Belapur, Navi Mumbai, Maharashtra, India-400614.

Received: 10 Oct 2022 / Accepted: 8 Nov 2022/ Published online: 01 Jan 2023

*Corresponding Author Email: dr.marar@yahoo.com

Abstract

Drug-induced hepatotoxicity is a significant cause of morbidity and is the major reason for withdrawal of therapeutic drugs from the commercial market. The objective of the existing study was to examine the changes in level of serum marker enzymes, liver toxicity and lipid peroxidation caused by administration of Methotrexate (MTX) and to determine protective efficiency of aqueous fruit extract of *Morinda citrifolia L* in reverting or suppressing detrimental effects of MTX induced hepatotoxicity in male Wistar rats. Methotrexate (MTX) is one of the folic acid antagonists widely used in the therapy of various types of diseases and malignancy. It induces cell damage by producing free radicals and reactive oxygen species. Aim of the present work was to investigate the histological and histochemical alterations in the liver of Wistar rat followed by administration of Methotrexate. Liver injury was assessed by investigating serum marker enzymes and liver levels of aspartate aminotransferase (AST), alanine aminotransferase (ALT), and lactate dehydrogenase (LDH) and was correlated to the histopathological observations in the liver. MTX increased the levels of lipid peroxides, AST, and ALT activity, but decreased serum LDH. Similarly, antioxidant activities like Superoxide dismutase (SOD), Catalase (CAT), Glutathione peroxidase (GPx), Glutathione-S-transferase (GST) and Glutathione reductase (GRD) were also affected due to MTX treatment. Pathological alterations were also observed in histology of the liver tissue with MTX treatment. Supplementation of *Morinda citrifolia L* fruit extract expressively prevented the MTX mediated pathological alterations in liver tissues with a decrease serum marker enzyme activity and a significant increase in antioxidant levels. The information gained in the existing study propose that *Morinda citrifolia L* fruit extract can offer substantial protective effect over drug which encouraged oxidative damage in rat liver.

Keywords

Methotrexate, *Morinda citrifolia L*, antioxidant enzymes, oxidative stress, hepatotoxicity, malignancy, histopathology.

INTRODUCTION:

Methotrexate (MTX) is an antineoplastic antimetabolite with immunosuppressant properties widely used clinically in systemic lupus erythematosus, rheumatoid arthritis, psoriasis, and neoplastic diseases [1]. It is an antimetabolite,

binding to the enzyme dihydrofolic acid reductase inhibiting the synthesis of tetrahydrofolate, required for synthesis of thymidylate, an essential component of DNA. Its therapeutic applications are limited due to the high incidence of serious dose-dependent toxicity, including hepatotoxicity, which causes

malabsorption and diarrhoea in the patients, renal damage, bone marrow suppression, and gastrointestinal mucosal inflammation [2,3]. MTX-associated hepatotoxicity has gained much more attention and is a significant clinical problem that affects patient compliance with MTX-containing regimens. Oxidative stress has emerged as a key player in the pathogenesis of MTX-induced hepatotoxicity [4]. Increased generation of reactive oxygen and nitrogen species, together with the decreased antioxidant defence, promotes the development and progression of hepatotoxicity. It has been reported that MTX causes oxidative stress in liver tissue [4]. Although 7-OH metabolite is the major pathway of MTX metabolism, MTX is metabolized and stored in hepatocytes in the polyglutamated form [5]. Major cause of hepatotoxicity is elevated levels of polyglutamates due to longer intracellular existence of the drug [6]. MTX has been suggested to inhibit dihydrofolate reductase, thereby affecting synthesis of thymidylate, indirectly suppressing DNA synthesis [7]. Additionally, it has been demonstrated that cytosolic nicotinamide adenosine diphosphate (NADP)-dependent dehydrogenases and NADP malic enzymes are inhibited by MTX, suggesting decrease in availability of NADPH in cells.

Morinda citrifolia L (Noni) is one of the important traditional folk medicinal plants, discovered by the ancestors of Polynesians and among the few medicinal plants being used over 2000 years [8,9]. Epidemiological studies have confirmed that consumption of fruits and vegetables may decrease free radical-induced oxidative damage and lipid peroxidation in cigarette smokers [10,11]. Noni juice has become a very popular supplement used by many cancer patients as a source of energy during chemotherapy however, there is limited information of its safety when used in combination with various chemotherapy agents [7]. It has been stated that numerous compounds like lipid soluble polyphenols, anthraquinones, α -tocopherol, and β -carotene including phenolics, alkaloids, damnacanthal, and flavonoids present may contribute to the antioxidant activity of *M. citrifolia* fruit juice (Noni) [9,12]. Most

natural antioxidant compounds have also been often proposed to work synergistically with each other to produce comprehensive effects to free radical attack. These studies encouraged us to investigate the efficacy of *Morinda citrifolia L* fruit extract against MTX induced oxidative stress and pathological alterations in liver of rats.

MATERIALS AND METHOD:

Drugs and chemicals: Methotrexate injection Folitrax -15 IP (15mg/ml) was purchased from IPCA pharmaceuticals, Mumbai, India. The fruits of *Morinda citrifolia L* were purchased from Abirami Botanicals, Tamil Nadu, India. It was authenticated by the Botany department of St. Xaviers College, Mumbai as *Morinda citrifolia L* belonging to family Rubiaceae with Blatter Herbarium specimen number 108. The fruits were air dried for 2 days and ground to fine powder. All other chemicals used were of high analytical grade and solvents were of Qualigen grade. The aqueous extract of Noni was prepared by cold maceration of 250 g of the shade-dried fruit powder in 500 ml of distilled water allowed to stand overnight and boiled for 5-10 minutes till the volume was reduced to half its original volume [13]. The solution was then cooled, filtered, concentrated, dried in vacuum (yield 36 g) and the residue stored in a refrigerator at 2-8°C for subsequent use.

Animal model: Adult male albino rats of Wistar strain (100 \pm 20 g) were obtained from Bharat Serum Pvt. Ltd, Thane, Navi Mumbai, India. The animals were maintained under standard conditions of temperature (25 \pm 2°C), light (12 h light/ 12 h dark) and humidity. They were fed standard rat pelleted diet obtained from Lipolin, India and water *ad libitum*. Experimental animals were handled according to the Institutional legislation, regulated by the Committee for the Purpose of Control and Supervision of Experiments on Animals (CPCSEA) India. (Registration number and date 1553/PO/a/11/CPCSEA Date 04/04/2012).

Experimental Design: Following the acclimatization period, the rats were randomly divided into groups consisting of six animals each and treated with MTX and Noni as per Table 1 [5,14].

Table 1. Mode of administration of Drug and Extract

Groups	Treatment (n=6)
Group I (Control)	Vehicle control (saline)
Group II (MTX 1)	5mg/kg bw of methotrexate IP twice weekly for 30 days
Group III (MTX 2)	1mg/kg bw of methotrexate IP twice weekly for 30 days
Group IV (Noni)	5mg/kg bw of concentrated <i>Morinda citrifolia L</i> aqueous fruit extract orally for 30 days
Group V (Noni +MTX 1)	5mg/kg bw of <i>Morinda citrifolia L</i> aqueous fruit extract orally + 5 mg/kg bw of methotrexate IP twice weekly for 30 days.

Group VI (Noni +MTX 2) 5mg/kg bw of *Morinda citrifolia* L aqueous fruit extract orally + 1 mg/kg bw of methotrexate IP twice weekly for 30 days.

At the end of the experimental period the animals were killed by cervical decapitation.

Trunk blood was collected from the decapitated site and centrifuged at 3000 rpm for 10 minutes within one hour of collection and enzymes were assayed. Liver was excised immediately, washed with ice-cold saline and stored in formalin before processing for histopathological studies.

Biochemical analysis:

Serum levels of aspartate aminotransferase (AST), alanine aminotransferase (ALT), and lactate dehydrogenase (LDH) were measured spectrophotometrically by standard IFCC/UV kinetic method using commercial kits Erba Mannheim IFCC Kinetic method [15].

Lipid peroxidation was determined by the procedure of Okhawa *et al.*, 1979[16]. Malondialdehyde (MDA), formed as an end product of lipid peroxidation, served as a measure of the intensity of oxidative stress. MDA reacts with thiobarbituric acid to generate a coloured product that can be measured optically at 532 nm. Tetramethoxy propane was used as standard.

Biochemical analysis of hepatic tissue:

The liver tissue was accurately weighed and homogenized with the help of Teflon-glass homogenizer in 0.01M Tris-HCl buffer (pH-7.4) for enzyme assays and in 0.15M KCl for lipid peroxidation studies. The aliquots of the homogenate were processed for the estimation of following biochemical parameters.

Estimation of antioxidant enzymes:

Superoxide dismutase (SOD) was assayed according to the method of Misra and Fridovich (1972) [17]. The method is based on ability of superoxide dismutase to inhibit auto-oxidation of adrenaline to adrenochrome at alkaline pH. Unit of enzyme activity is defined as the enzyme required for 50% inhibition of adrenaline autooxidation. Catalase activity was measured using the method of Clairborne (1985) [18], with hydrogen peroxide as a substrate. The method relies on decomposition of hydrogen peroxide which is indicated by decrease in absorbance at 240nm. Glutathione -S-transferase (GST) activity was estimated [19]. This method is based on enzyme catalysed condensation of glutathione with the model substrate, 1-chloro,2,4-dinitrobenzene. The product formed (2,4 dinitrophenyl-glutathione) absorbs light at 340nm facilitating analysis of enzyme activity based on product formation. Glutathione Peroxidase (GPx) assay which is dependent on oxidation of NADPH at

340nm using hydrogen peroxide[20]. Glutathione Reductase (GRD) activity was measured [21]. In the presence of glutathione reductase, hydrogen is transferred from NADPH to GSSG, and reaction is monitored at 340 nm spectrophotometrically.

Assessment of non-enzymatic antioxidants: Total Reduced Glutathione (GSH) was estimated, where the colour developed was read at 412nm [22].

Estimation of diagnostic marker enzymes: The aminotransferases are most frequent indicator of hepatotoxicity. Aspartate Aminotransferase (AST) and Alanine Aminotransferase (ALT) both were estimated [15], wherein former DL-Aspartate and later DL-Alanine was used as substrate. Lactate Dehydrogenase (LDH) was also assayed [15], and Alkaline Phosphatase (ALP) and Acid Phosphatase (ACP) based on method from Bergmeyer *et al.*, (1974) [23]. Total protein was estimated [24].

Statistical analysis:

The results were expressed as mean \pm standard deviation (SD) for six animals in each group. Statistical significance of assay was analyzed by unpaired Students t-test and given respective symbols in the tables.

RESULTS:

Histology and Serum Parameters:

Drug-induced liver injury (DILI) is a major concern in chemotherapy especially because of initiation by a free radical's reaction mechanism. Antioxidants play an important role to protect the cells and tissues against damage by ROS. In this study we have evaluated the modulating effects of *Morinda citrifolia* L. on MTX induced alterations in liver cells by histopathology and co-related the observations with serum and tissue parameters to assess the toxicity.

No appreciable changes were observed in histology of control rats (Plate1), signifying normal architecture. Rats treated with MTX1 showed marked histopathological abnormalities which involved dissolution of hepatic cords and appearance of empty vacuoles aligned by strands of necrotic hepatocytes. Hepatic tissues exhibited the advent dense tendency for liver fibrosis manifested by focal inflammatory cells or necrotic tissues and the presence of many spots of focal cellular granulomatous lesions (Plate. 2, 3) when compared with control rats' liver (Group I). Liver histology of animals receiving *Morinda citrifolia* L. fruit extract alone (Group IV) did not display any noteworthy

pathological changes signifying that it does not have any adverse effect (Plate. 4). When compared to the MTX treated rats (Plate. 5, 6) histology of liver of

animals co-treated with *Morinda citrifolia L.* fruit extract and MTX showed pathological variations but to lesser extent.

Histopathological studies- Light microscopy of Liver Tissue

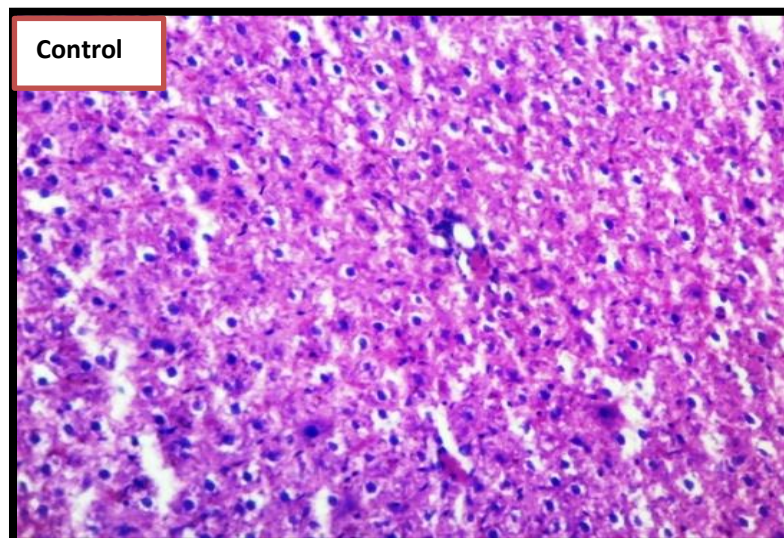


Plate 1 Histology of rat liver tissue Control (Group I).

Histology of normal control (Group I) rat liver showing normal architecture after staining with haematoxylin and eosin stain, magnification X 400.

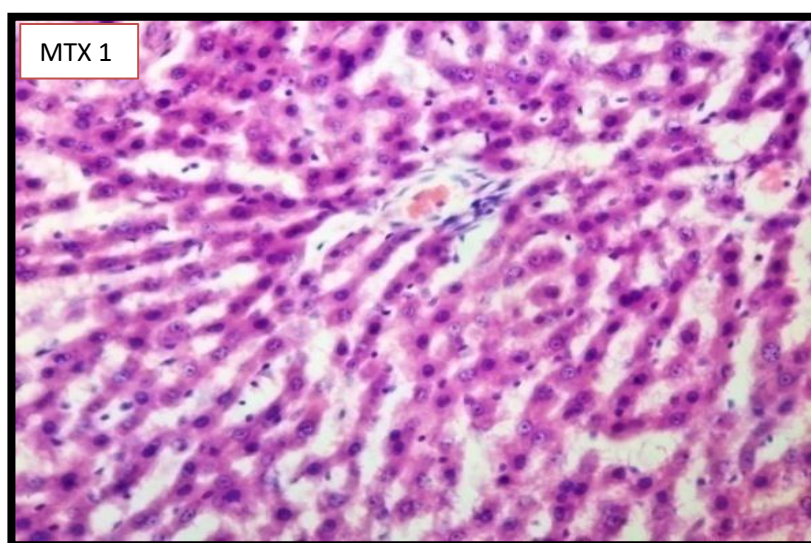


Plate 2 Histology of rat liver tissue treated with MTX (Group II)

Pronounced histopathological abnormalities seen in liver of rats treated with Methotrexate (5mg/kg body weight) (Group II) showing mild degeneration (+) of Parenchymatous hepatocytes and severe periportal infiltration of inflammatory cells (+++) after staining with haematoxylin and eosin stain, magnification X 400.

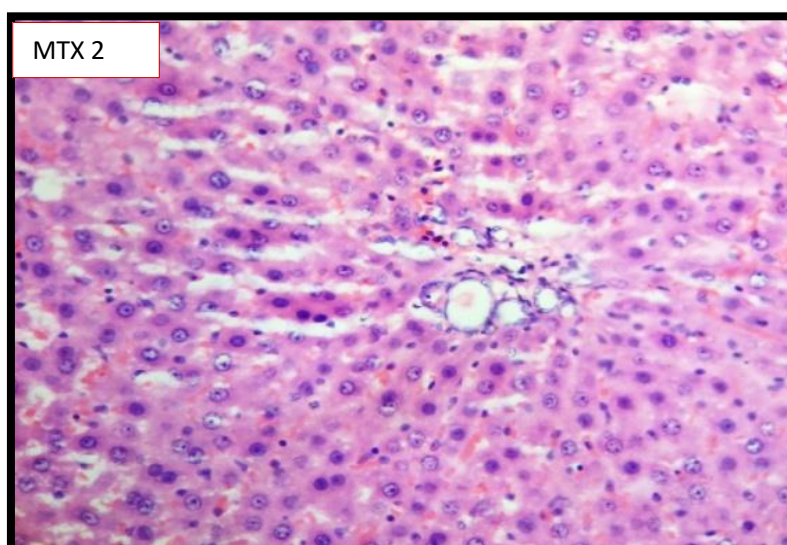


Plate 3 Histology of rat liver tissue treated with MTX 2 (Group III)

Histology abnormalities of methotrexate (Group III) (1mg/kg body weight) treated rat liver showing moderate periportal infiltration of inflammatory cells (++) and mild hepatocyte degeneration after staining with haematoxylin and eosin stain, magnification X 400.

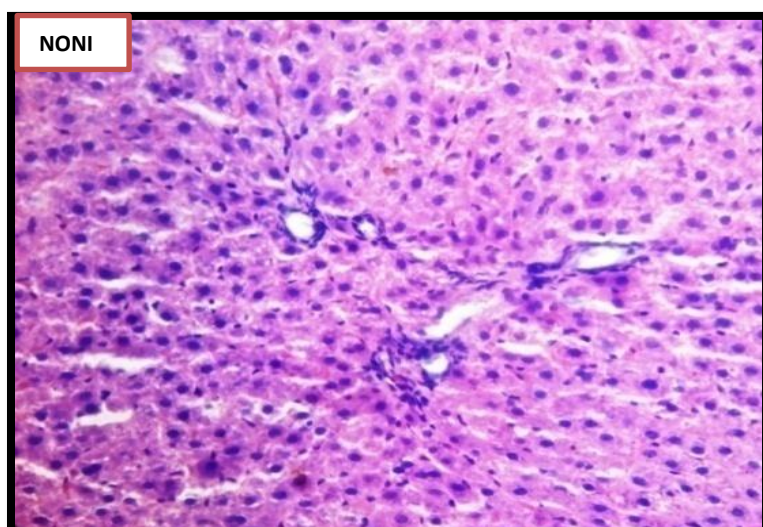


Plate 4 Histology of rat liver tissue treated with Noni (Group IV)

Histology of *Morinda citrifolia L.* fruit extract (5 mg/kg body weight) (Group IV) showing no significant pathological difference from control rat liver after staining with haematoxylin and eosin stain, magnification X 400.

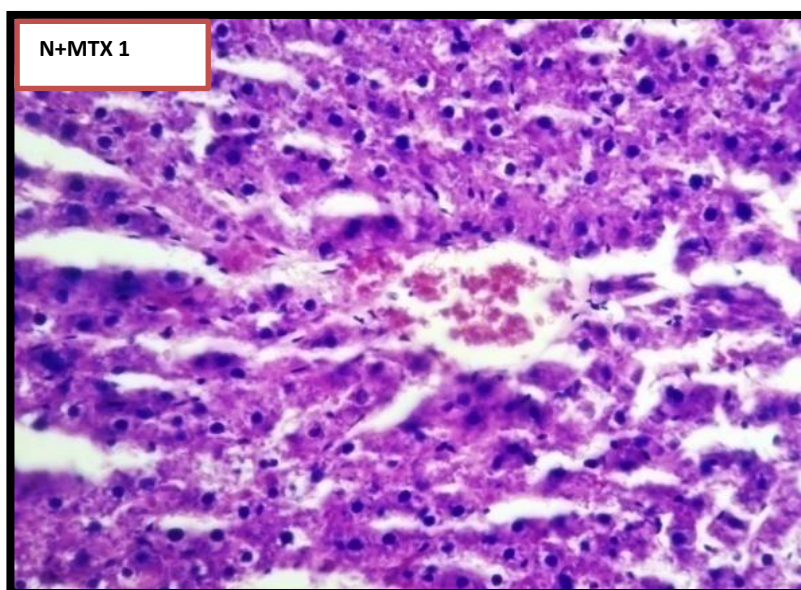


Plate 5 Histology of rat liver tissue treated with N+MTX 1 (Group V).

Histopathology seen in rats treated with methotrexate (5 mg/kg body weight) and *Morinda citrifolia* L. (5mg/kg body weight) (Group V). There was moderate degeneration (++) of centrilobular hepatocytes after staining with haematoxylin and eosin stain, magnification X 400.

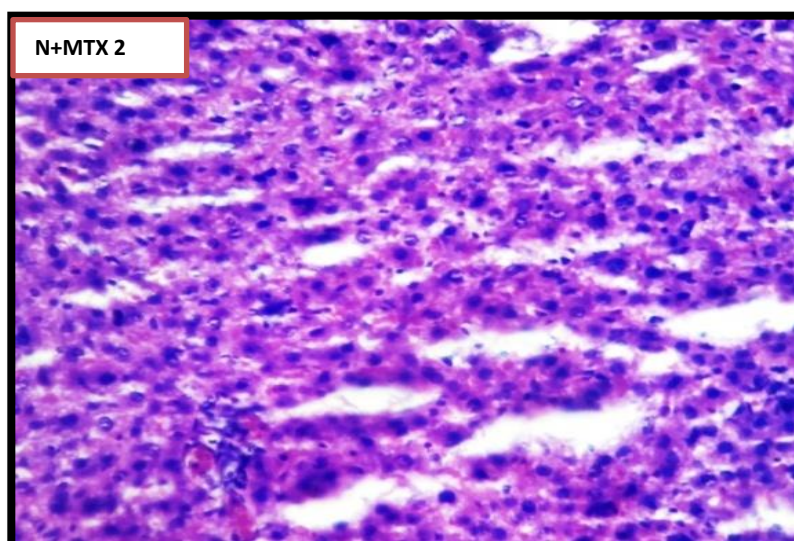


Plate 6 Histology of rat liver tissue treated with N + MTX 2 (Group VI)

There was mild periportal infiltration of inflammatory cells (+) seen in rats treated with methotrexate (1 mg/kg body weight) and *Morinda citrifolia* L. (5mg/kg body weight) (Group VI). after staining with haematoxylin and eosin stain, magnification X 400.

Effect of *Morinda citrifolia L.* fruit extract on MTX induced changes in serum enzymes:

Serum enzymes and enzyme profiles are indicators of liver and biliary tract disease. Damage or necrosis of hepatocytes, demonstrating increased permeability

can be the reason for elevated levels of serum marker enzymes namely AST, ALT, LDH in the serum of MTX treated animals as compared to controls (Table 2).

Table 2 Effect of methotrexate and *Morinda citrifolia L.* on serum enzymes present in liver tissue.

Parameters	Group I C	Group II MTX1	Group III MTX 2	Group IV Noni	Group V Noni + MTX 1	Group VI Noni + MTX 2	ANOVA P - Value
AST (IU/L)	280.30±6.00	646.15±14.00 ^{a***}	540.15±31 ^{b***}	247.21±30.00 ^{c*}	423.27±14.00 ^{d***}	345.73±31.00 ^{e***}	0.001
ALT (IU/L)	296.00±3.90	840.07±19.00 ^{a***}	540.15±31 ^{b***}	319.50±10.00 ^{c***}	423.27±14.00 ^{d***}	345.73±31.00 ^{e***}	0.001
Serum LDH (nmoles of pyruvate/mg protein)	458.±15.00	524.93±19.00 ^{a***}	489.27±14 ^{b*}	476.06±15.00 ^{cNS}	499.27±14.00 ^{d*}	482.17±14.00 ^{eNS}	0.001

Values are expressed as Mean ± SD for six rats in a group. Statistical significance was tested with ANOVA and complemented with Student's t-test; Values carrying different superscripts are significantly different. Comparisons are expressed as 'a' Group I and Group II, 'b' Group I and Group III, 'c' Group I and Group IV, 'd' Group II and Group V, 'e' Group III and Group VI'. Statistical significance represented as: * p < 0.05, ** p < 0.01, *** p < 0.001, NS- Non-significant.

Hepatotoxicity induced by drug can lead to liver injury. There are reports suggesting MTX administration leading to MTX polyglutamate accumulation causing toxicity. Conversion of MTX to its major extracellular metabolites, 7-hydroxy methotrexate takes place in liver, where it is oxidised

by soluble enzymatic system [25]. MTX treated rats showed increase in LDH, ACP and ALP in serum indicating liver injury (Table 3) as corroborated by our histopathological studies which shows hepatobiliary inflammation, increased permeability, stress and necrosis of hepatocytes [26,27].

Table 3 Effect of methotrexate and *Morindacitrifolia L.* fruit extract on levels of enzymes present in liver tissue.

Parameters	Group I C	Group II MTX1	Group III MTX 2	Group IV Noni	Group V Noni+MTX 1	Group VI Noni+MTX 2	ANOVA P -Value
LDH (µg moles of pyruvate/mg protein)	1.54±0.16	4.25±0.05 ^{a***}	2.87±0.18 ^{b***}	1.8±0.18 ^{c*}	3.08±0.23 ^{d*}	2.13±0.10 ^{e***}	0.001
ALP (µM of PNP/mg protein)	2.15±0.64	8.06±0.93 ^{a***}	6.01±0.91 ^{b***}	3.08±0.98 ^{cNS}	4.11±0.40 ^{d***}	3.84±0.59 ^{e***}	0.001
ACP (µM of PNP/mg protein)	11.84±0.80	25.60±0.55 ^{a***}	15.37±0.23 ^{b***}	12.67±0.83 ^{cNS}	17.90±0.99 ^{d***}	17.35±0.23 ^{e***}	0.001
AST (nmoles of Pyruvate /min/mg protein)	2.01±0.09	0.92±0.006 ^{a***}	1.78±0.008 ^{b**}	2.24±0.106 ^{cNS}	1.83±0.093 ^{d***}	2.09±0.13 ^{e***}	0.001
ALT (nmoles of Pyruvate /min/mg protein)	1.87±0.18	1.4±0.25 ^{a**}	1.70±0.05 ^{b*}	1.82±0.119 ^{c***}	1.55±0.26 ^{dNS}	1.79±0.13 ^{e***}	0.001
Total Protein (µg/ml)	115.49±3.36	71.96±1.32 ^{a***}	87.54±3.5 ^{b***}	114.90±2.8 ^{cNS}	86.54±3.56 ^{d***}	96.93±1.43 ^{e***}	0.001

Values are expressed as Mean \pm SD for six rats in a group. Statistical significance was tested with ANOVA and complemented with Student's *t*-test; Values carrying different superscripts are significantly different. Comparisons are expressed as 'a' Group I and Group II, 'b' Group I and Group III, 'c' Group I and Group IV., 'd' Group II and Group V, 'e' Group III and Group VI. Statistical significance represented as: * $p < 0.05$, ** $p < 0.01$, *** $p < 0.001$, NS- Non-significant. One way analysis revealed that all the tissue marker enzymes parameters are significant with $p < 0.05$.

MTX treatment led to decrease in levels of hepato-specific enzymes like AST and ALT in liver tissue in Group II (MTX 1) in comparison to that of control, but Group III (MTX 2) had levels near to control (Table 8). AST and ALT are cytosolic enzymes, metabolising amino acids to α -keto acids [28,29]. Animals that received *Morinda citrifolia L* fruit extract (Group IV) were found to be almost near to control values (Table 3). Animal in Group V and VI also showed lesser effect of MTX in comparison to animals treated only with MTX.

Total protein was found to have decreased severely in MTX treated animals indicating liver damage, chiefly causing protein loss or due to deficiency of dietary protein as there was decrease in feed intake by animals injected with MTX (Table 3). MTX has

been reported to inhibit enzymes necessary for transcription hence can suppress protein synthesis [7,30,31]

Influence of Noni on MTX induced alteration in levels of lipid peroxides and non-enzymic antioxidants:

Steady state of ROS concentration is maintained and regulated by a balance between their rates of production and removal by various antioxidants. Hence concentration of reducing species like GSH, NADH, NADPH and FADH needs to be sustained in each cell. MTX not only caused a significant increase in an oxidative stress biomarker (TBARS) but also a significant decrease in the status of antioxidants in the liver following administration of the drug.

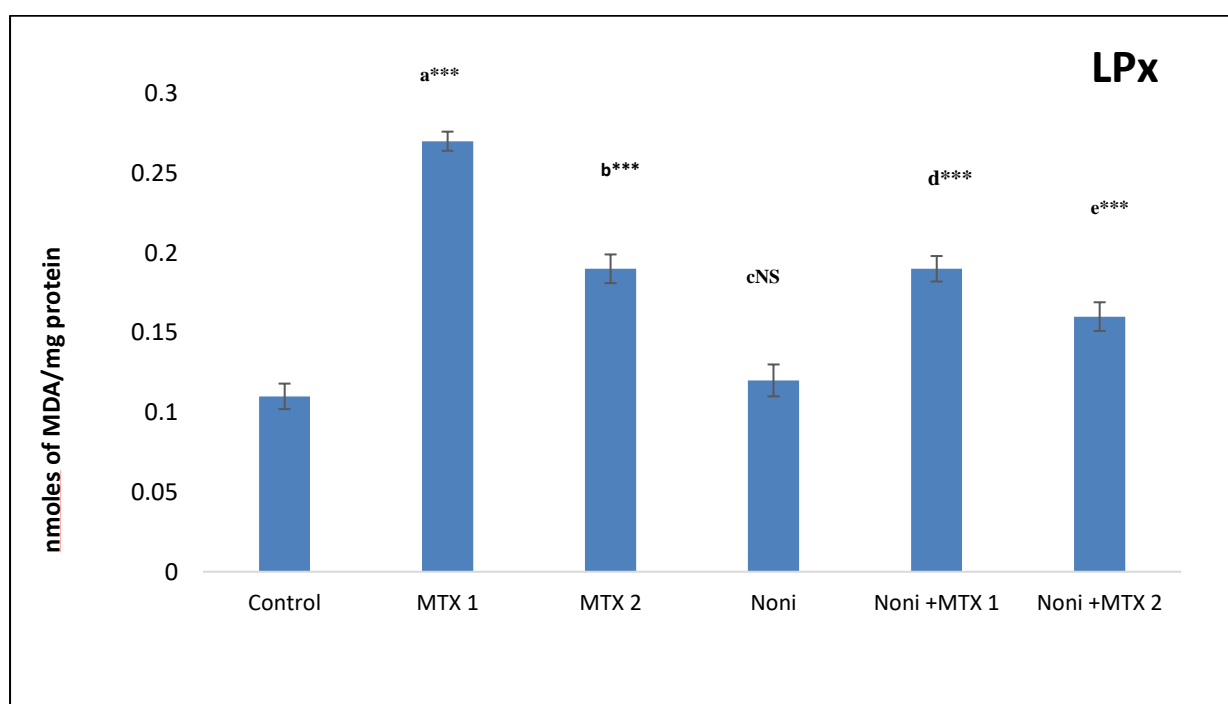


Figure 1 Effect of Noni on MTX mediated changes in LPx levels in liver tissue.

Values are expressed as Mean \pm SD for six rats in a group. Statistical significance was tested with ANOVA and complemented with Student's *t*-test; Values carrying different superscripts are significantly different. Comparisons are expressed as 'a' Control and MTX 1, 'b' Control and MTX 2, 'c' Control and Noni, 'd' MTX 1 and Noni +MTX 1, 'e' MTX 2 and Noni +MTX 2. Statistical significance represented as: *** $p < 0.001$, NS-Non-significant.

Malondialdehyde (MDA), which is a marker for lipid peroxidation, was found to be significantly elevated in Group II (MTX1) treated groups ($p < 0.001$) (Fig. 1). This is indicative of the pro-oxidant nature of methotrexate.

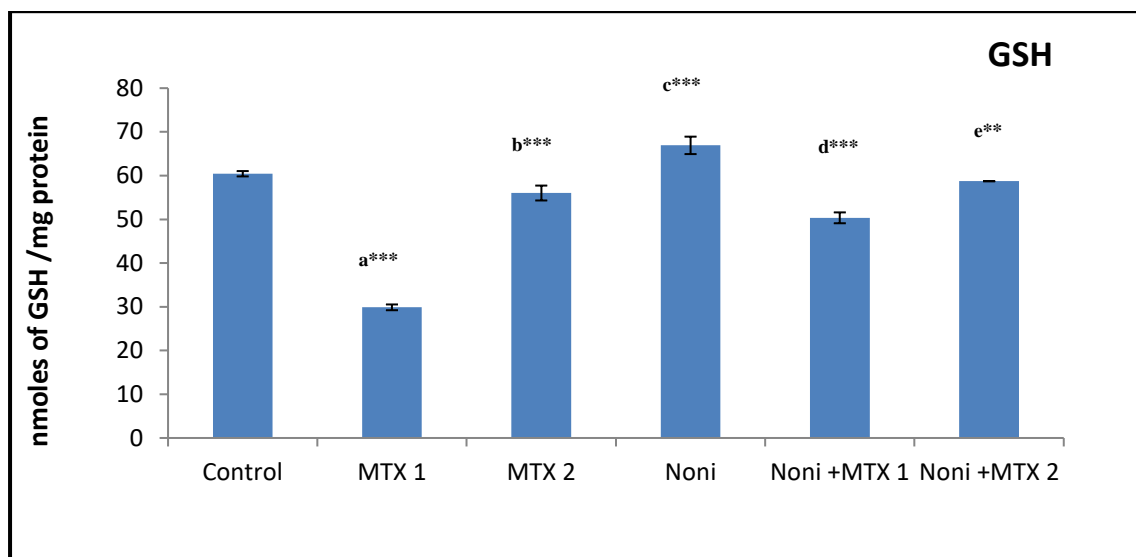


Figure 2 Effect of Noni on MTX mediated changes in GSH levels in liver tissue.

Values are expressed as Mean \pm SD for six rats in a group. Statistical significance was tested with ANOVA and complemented with Student's *t*-test; Values carrying different superscripts are significantly different. Comparisons are expressed as 'a' Control and MTX 1, 'b' Control and MTX 2, 'c' Control and Noni, 'd' MTX 1 and Noni +MTX 1, 'e' MTX 2 and Noni +MTX 2. Statistical significance represented as: ** $p < 0.01$, *** $p < 0.001$.

Compared to controls there was decrease in hepatic GSH in MTX 1 treated rats (Fig. 2) which can also be attributed to the prooxidant nature of MTX and impairment of hexose monophosphate (HMP) shunt [26].

Effect of Noni against MTX induced alterations in the activity of antioxidant enzymes in liver:

We observed that there was elevation in activities of SOD, CAT, GST and GPX in MTX treated groups Group II and III ($p < 0.001$) (Table 4) where in Group II MTX 1 the elevation was higher comparison to that of MTX 2.

A significant increase ($p < 0.001$) in GST levels was observed in Group II and III (Table 3). GRD activities revealed a significant decrease in MTX treated Group II ($p < 0.001$) (Table 4) in comparison to that of Group III ($p < 0.05$). In Noni alone treated rats (Group IV) GRD activities appeared to be near normal when compared to control. Rats co-administered with Noni and MTX (Group V, Group VI) also showed improvement in levels in comparison to that of MTX alone (Table 4).

Table 4 Effect of Noni on MTX mediated changes on antioxidant enzymes in liver tissue.

Parameters	Group I C	Group II MTX1	Group III MTX 2	Group IV Noni	Group V Noni+MTX 1	Group VI Noni+MTX 2	ANOVA P -Value
SOD (units/mg protein)	2.2 \pm 0.22	5.25 \pm 0.22 ^{a***}	3.89 \pm 0.07 ^{b***}	2.71 \pm 0.07 ^{c**}	3.80 \pm 0.13 ^{d*}	3.5 \pm 0.46 ^{e**}	0.001
CAT (μ mol of H ₂ O ₂ consumed/min/mg protein)	1.7 \pm 0.05	2.37 \pm 0.22 ^{a***}	2.02 \pm 0.26 ^{b***}	1.79 \pm 0.071 ^{cNS}	1.97 \pm 0.14 ^{d***}	1.74 \pm 0.10 ^{e***}	0.001
GST (μ moles of CDNB conjugated/min/mg protein)	1.28 \pm 0.03	2.13 \pm 0.26 ^{a***}	1.59 \pm 0.10 ^{b***}	1.36 \pm 0.04 ^{c**}	1.56 \pm 0.12 ^{d***}	1.37 \pm 0.03 ^{e***}	0.001
GRD (nmoles of NADPH oxidized/min/mg protein)	0.34 \pm 0.03	0.20 \pm 0.01 ^{a***}	0.30 \pm 0.03 ^{b*}	0.36 \pm 0.02 ^{cNS}	0.24 \pm 0.03 ^{d*}	0.34 \pm 0.02 ^{e*}	0.001
GPx (nmoles of NADPH oxidized/ min/ mg protein)	0.44 \pm 0.02	0.69 \pm 0.03 ^{a***}	0.58 \pm 0.01 ^{b***}	0.47 \pm 0.02 ^{c*}	0.59 \pm 0.02 ^{d***}	0.56 \pm 0.03 ^{eNS}	0.001

Values are expressed as Mean \pm SD for six rats in a group. Statistical significance was tested with ANOVA and complemented with Student's *t*-test; Values carrying different superscripts are significantly different. Comparisons are expressed as 'a' Group I and Group II, 'b' Group I and Group III, 'c' Group I and Group IV, 'd' Group II and Group V, 'e' e'Group III and Group VI. Statistical significance represented as: * $p < 0.05$, ** $p < 0.01$, *** $p < 0.001$, NS- Non-significant. One way analysis revealed that all the antioxidant enzymes in liver tissue are significant with $p < 0.05$.

GPx activity were found to have elevated double fold in Group II and III MTX treated rats. As the dose was lower in Group III MTX 2 the levels of GPx activity were found to be lesser in comparison to that of Group II MTX 1 (Table 4).

DISCUSSION:

This study is an investigation on the effect of *Morinda citrifolia L* extract on methotrexate induced liver toxicity. Animals treated with MTX showed histopathological changes in liver with degeneration of parenchymatous hepatocytes and severe periportal infiltration of inflammatory cells, whereas animals treated with lower dose showed moderate periportal infiltration of inflammatory cells and mild hepatocyte degeneration. Our results agree with similar results, who have reported in histopathology of liver in rats treated with MTX [7,32,33,34]. In animals treated with Noni and MTX there was mild periportal infiltration of inflammatory cells, but overall combination therapy showed significant recovery when compared to only MTX treatment. Elevation in AST and ALT levels in the serum is indicative of hepatocellular injury. Animals that received *Morinda citrifolia L* fruit extract alone AST and ALT activities were found to be in reference range. Significant normalization in the levels of transaminases was observed in animals cotreated with *Morinda citrifolia L* fruit extract and MTX when compared to enzyme levels of only MTX treated rats Liver damage induced by MTX can be reversed by *Morinda citrifolia L* fruit extract maybe because it protects the structural integrity of the membranes which averts the leakage of intracellular enzymes [35,36,37].

Increased LDH levels can be attributed to a response to anaerobic conditions. and its raised levels in serum may be due to acute liver injury causing enzyme leakage through damaged hepatocyte membranes [38]. Noni treated animal had their LDH values near to control demonstrating the nontoxic nature of Noni. Animals treated with combination of Noni and MTX 1 had increase in LDH levels in serum but not as high as compared to that of MTX alone [39].

Compromising aerobic respiration can lead to increase in LDH level and increase in anaerobic respiration to meet energy demands, indicates reduced Krebs's cycle activity [40]. Animals treated

with Noni did not show any significant change as compared to control, but the animals treated with combination of Noni + MTX had a dose dependent reversal in LDH levels again suggesting protective effect of Noni on MTX treated animals.

Alkaline Phosphatase, which is a hydrolase enzyme, hydrolyses phosphates at alkaline pH and serving as a marker enzyme of plasma membrane and endoplasmic reticulum in evaluating the integrity of the membrane [41].

Animals treated with *Morinda citrifolia L* fruit extract along with MTX showed a significant recovery in activity of phosphatase in comparison to enzyme levels of only MTX treatment (Table 3). Similar results of ameliorative effect of Ginseng on MTX treated animals has been reported by [36,37].

Co-treatment of MTX with Noni showed significant stabilization in the levels of transaminases when compared to enzyme levels of MTX treated rats (Group II and III) (Table 3) hence substantiating the protective effect of Noni from toxic exogenous exposures. As reported by Ghosh *et al.*, [42], this could be possibly due to active phytochemical constituents present in *Morinda citrifolia L* fruit extract which might have alleviated anti-inflammatory effects.

Total protein content was found to have decreased due to MTX treatment in Group II and Group III. Change in total protein content in liver tissue was found to be non-significant in groups treated with *Morinda citrifolia L* alone (Group IV) (Table.3). In groups co-treated with *Morinda citrifolia L* fruit extract and MTX (Group V and VI) had improved protein levels. Similar effect of Noni in combination with NH₄Cl and found that the protein levels had normalized when compared with control [43].

Disturbance in these normal redox states of tissue can cause toxic effects leading to production of peroxides and free radicals that can damage cell components including lipids, proteins and DNA [44]. Levels of lipid peroxides increased in MTX treated groups [1,26]. Tissue damage can be extensively aroused due to these free radicals, harming membrane lipids, proteins and nucleic acids [45,46]. Supplementation with Noni decreased levels of MDA, Noni has excellent antioxidant and scavenging activity, which can guard individuals from oxygen

free radicals, superoxide anion radicals (SAR) and quench lipid peroxides (LPO) [47].

MTX combination treatment with Noni showed lesser levels of lipid peroxides when compared to MTX alone. This might be due to antioxidants present in Noni, primarily the lipid soluble ones which could have exerted a profound effect on inhibition of free radical generation and lipid peroxidation [45]. Similar results on alleviated MTX induced oxidative damage have been reported [48], suggesting caffeic acid phenethyl ester (CAPE) prevents methotrexate-induced hepatorenal oxidative injury.

Antioxidants protect human body from free radicals and reactive oxygen species (ROS) by removing and repairing oxidant damage caused [49,50]. Enzymes play an important role in combating free radical induced oxidative stress leading to alteration in enzymatic antioxidant status [51].

GSH is the most important biological non-enzymatic antioxidant, which forms the first line of defence against oxidative damage. Levels of GSH showed a MTX dose dependent change MTX inhibits the synthesis of cytosolic nicotinamide adenosine diphosphate (NADP)-dependent dehydrogenase and NADP malic enzymes thereby leading to decrease in NADPH in cells has also reported decreases in glutathione levels when mice were treated with MTX [32,38].

Level of GSH in animals treated with Noni extract alone where higher showing Noni had a sparing effect in the use of GSH as an antioxidant. Similarly, the animal treated in combination with Noni and MTX showed that the Noni extract might have modulated levels of hydroxyl radical and GSH [25,5,52], Jahovic N, Katherine S and Bardrul AM reports of similar benefits of methanol extract of *Oxalis corniculata*, suggesting ability of plant extracts to reactivate hepatic glutathione reductase reflecting decrease in lipid peroxidation.

Aerobic organisms have antioxidant defense mechanisms for removal and repair of damaged macro molecules. Antioxidants protect human body from free radicals and reactive oxygen species (ROS) effect [49,50]. SOD catalyses the dismutation of oxygen radicals to H_2O_2 . In liver of Noni treated rat, SOD levels were near control, Rats co administered with Noni and MTX) also showed betterment in levels in comparison to that of MTX alone.

This is in agreement with several studies on MTX inducing oxidative stress in tissues accompanied with alterations in antioxidant levels [38,54,55]. Free radicals activated by MTX are scavenged by SOD and CAT. Our results suggest that Noni might have a protective effect which reverts the oxidative stress caused by MTX. Similar results have been reported

suggesting increase in SOD activity is dose dependent in presence of MTX [36,37,55]. The increase in SOD activity in animals exposed to MTX can be due to production of free radicals that induced SOD activity to cope up with the oxidative stress.

Catalase activities were also found to be elevated in MTX treated was also reported [39]. Animal treated with Noni alone had normal CAT activity indicating Noni's ability to scavenge free radicals more efficiently [45]. Combination therapy (Noni with MTX) showed significant reversal in the increase suggesting protective effect of antioxidant supplementations on catalase activity [36,37,54].

GST's primary role is to catalyse reaction by detoxifying xenobiotics which leads to nucleophilic attack by GSH on electrophilic sulphur, nitrogen, or carbon atoms of nonpolar xenobiotic substrates, thereby inhibiting their interaction with cellular proteins and nucleic acids. Increase in activity of GST in MTX treated groups can be attributed to its involvement in biotransformation of MTX. Similar results have been reported suggesting beneficial effects of plant extract as antioxidant [55,56]. Co-administration of Noni with MTX helped maintain GST levels. Similar results have been reported suggesting protective effect of quercetin on MTX induced alteration in GST activity [38].

Oxidative stress induced tissue damage due to MTX [36,37]. An efficient modulatory effect was observed in rats co administered with Noni and MTX, Antioxidant activity of Noni may be due to polyphenols and anthraquinone present in it. Many natural phytochemicals possess antioxidant activity, including phenolics, damnacanthal, alkaloids and flavonoids [11,12, 57].

Function of intracellular GPx is degradation of H_2O_2 and hydroperoxides of free fatty acids, it also catalyses degradation of H_2O_2 and hydroperoxides of phospholipids inhibiting peroxidation process. GPx activity was found to be normal in Noni treated animal as compared to MTX treated groups [58,59]. Treatment with Noni could have stabilized the activity of the enzyme and hence help in avoiding free radical generation [60]. Groups co-administrated with Noni and MTX also had GPx activity reduced in comparison to that of MTX alone treated groups. Noni might have ability to enhance antioxidant defense mechanisms and antioxidant enzymes. Similar modulating effect of Ginseng on MTX induced changes in rats [37] have been reported.

CONCLUSION

From our experimental work we can conclude that, MTX treatment for both the doses resulted in toxicity

by altering levels of marker enzymes, enzymic and non-enzymatic antioxidants. Our biochemical findings were also supported by histopathological analysis. Animals treated with MTX and co supplemented with Noni had their values near to control, showing that Noni has the potential to reverse the toxicity caused by MTX, thus indicating its protective effect against drug-induced liver toxicity.

AUTHORS' CONTRIBUTION

Experimental work was designed by Corresponding author Dr. Thankamani Marar, reviewed the manuscript, and also put a lot of efforts to improve the quality of the manuscript. All the laboratory work, data collections, and manuscript writing was carried out by Dr Bhakti A Mhatre.

CONFLICTS OF INTEREST

There has been no financial support for this work that could have influenced its outcome and we wish to confirm that there are no known conflicts of interest associated with this publication.

REFERENCES

1. Moghadam A R Tutunchi S Namvaran-abbas-abad A Yazdi M and Bonyadi F. Pre-administration of turmeric prevents methotrexate-induced liver toxicity and oxidative stress Pre-administration of turmeric prevents methotrexate-induced liver toxicity and oxidative stress. BMC Compl Alt Med 2015 ; (15). doi: 10.1186/s12906-015-0773-6.
2. Triantafyllou K Vlachogiannakos J Ladas SD. Gastrointestinal and liver side effects of drugs in elderly patients. Best Pract Res Clin Gastroenterol 2010; 24(2):203–215.
3. Duman DG Kumral ZN Ercan F Deniz M Can G Çağlayan YB. Saccharomyces boulardii ameliorates clarithromycin-and methotrexate-induced intestinal and hepatic injury in rats. Br J Nutr 2013; 110(03):493–499.
4. Faten R A Ibrahim A E & Khaled A E. Protective and modulatory effects of Curcumin and L-Carnitine against Methotrexate-induced Oxidative stress in albino rats. Research Journal of Pharmaceutical, Biological and Chemical Sciences 2013; 4:744–754.
5. Katherine S Anjali G Judith AS. Evaluation of the Hepatic Metabolism and Antitumor Activity of Noni Juice (*Morinda citrifolia* L.) in Combination with Chemotherapy. J Society for Inte Onco 2010; 8:89-94.
6. Akram M A. Histological and histochemical studies on the effects of methotrexate on the liver of adult male albino rat. Int. J. Morpho 2006;24:417–422.
7. Patel NN Ghodasara D. Subacute toxicopathological studies of methotrexate in Wistar rats. Dave Veterinary World 2014; 223:489–495.
8. Morton JF. The ocean going Noni, or Indian mulberry (*Morinda citrifolia*, *Rubiaceae*) and some of its colourful relatives. Ecol Bot 1992; 46:241-256.
9. Serafini MR Santos RC Guimarães AG. Morinda citrifolia Linn leaf extract possesses antioxidant activities and reduces nociceptive behavior and leukocyte migration. J Med Food 2011; 14: 1159-66.
10. Wang MY Anderson G Nowicki D and Jensen J. Hepatic protection by noni fruit juice against CCl₄ induced chronic liver damage in female SD rats. Plant Foods Hum Nutr 2008; 63(3):141-145.
11. Sharma B and Sharma UK. Hepatoprotective activity of some indigenous plants. Int J PharmTech Res 2010; 2(1): 568-572.
12. Alshatwi AA Shafi G and Hasan TN. Apoptosis mediated inhibition of human breast cancer cell proliferation by lemon citrus extract. Asian Pac J Cancer Prev 2011; 12: 1555-1559.
13. Kharis Z Hawariah LP Normah A and Aishah R. *Morinda citrifolia* extract inhibits proliferation of non-small human lung cancer cell line NCI-H23 via apoptosis by modulating the Bax : Bcl-2 ratio. J Trop Agric Fd Sc. 2010; 38(2): 203–209.
14. Pinkerton CR and Milla PJ. Methotrexate enterotoxicity: Influence of drug dose and timing in rat. Br. J. Cancer 1984; 49:97-101.
15. King J. The transferases- alanine and aspartate transaminases. In Practical Clinical Enzymology. Ed. King J. London: Van Nostrand Company Ltd, 1965; pp: 121-138.
16. Ohkawa H Ohishi N and Yagi K. Assay for lipid peroxides in animal tissues by thiobarbituric acid reaction. Anal Biochem, 1979; 95: 351-358.
17. Misra HP and Fridovich I. The generation of superoxide radical during the autoxidation of ferredoxin. J Biol Chem 1971; 246: 6886-6890.
18. Claiborne A. Catalase activity. In Handbook of Methods for Oxygen Radical Research. Ed. Greenwald RA. Boca Raton, 1st edn CRC Press, 1985; pp. 283-284.
19. Habig WH Pabst MJ and Jakoby WB. Glutathione S-transferases, the first enzymatic step in mercapturic acid formation. J Biol Chem 1974; 249: 7130-7139.
20. Paglia DE and Valentine WN. Studies on the quantitative and qualitative characterization of erythrocyte glutathione peroxidase. Lab Clin Med 1967; 70: 158-169.
21. Carlberg I Mannervik B. Purification and characterization glutathione reductase from calf liver- An improved procedure for affinity chromatography on 2', 5'-ADP Sepharose 4B, Anal Biochem, 1981; 116, 531-536.
22. Moron MS Depierre JW and Mannervik B. Levels of glutathione, glutathione reductase and glutathione-S-transferase activities in rat lung and liver. Biochem Biophys Acta 1979; 582:67-78.
23. Bergmeyer H U Gawehn K and Grassl M. Methods of Enzymatic Analysis, (Bergmeyer H.U.) (2) edn Academic Press, Inc., New York, NY 1974; pp.495-496.
24. Lowry OH Rosenbrough NJ Farr AL and Randall RJ. Protein measurement with the folin phenol reagent. J Biol Che 1951; 193: 265-275.

25. Jahovic N and Iya HC. Melatonin prevents methotrexate-induced hepatorenal oxidative injury in rats. *J Pineal Res* 2003; 34:282–288.
26. Jwied AH. Hepatoprotective Effect of the aqueous extract of *Camellia sinensis* against methotrexate-induced liver damage in rats. *Iraqi J Pharm Sci* 2009; 18(2): 73-79.
27. Highland HN Kanwar R Engineer A and Desai KR. Effective alleviation of methotrexate induced hepatotoxicity by *Murraya koenigii* leaf extracts. *Eur J Pharama Med Res* 2016; 3(6): 439-447.
28. Dhir V and Dhand P. Toxicological approach in chronic exposure to lead on reproductive functions in female rats (*Rattus norvegicus*). *Toxicol. Int* 2010; 17: 01-07.
29. Maiti R Jana D Das U and Ghosh D. Antidiabetic effect of aqueous extract of seed of *Tamarindus indica* in streptozotocin-induced diabetic rats. *J Ethnopharmacol* 2004; 92; (1) 85-91.
30. Vaghasiya J Bhalodia Y and Rathod S. 'Drug induced hepatotoxicity. Effect of polyherbal formulation. *Phcog Mag* 2009; 5:232-237.
31. Perianayagasamy AM Gomez PP and Dhasarathan P. Therapeutical effect of melatonin and glutamine against rat's bone marrow toxicity induced by methotrexate. *J Bio Sci Res* 2010; 1(3): 202-207.
32. Hemeida RA. Mohafez OM. Curcumin attenuates methotrexate-induced hepatic oxidative damage in rats. *J Egyptian Nat Cancer Ins*, 2008; 20(2):141–148.
33. Hadi NR Swadi AA and Mohammad BI. Hepatoprotective potential of metformin against methotrexate induced hepatotoxicity. *Asian J Exp Biol Sci* 2012; 3 (1): 110 – 117.
34. Uraz S Tahan V Aygun C Fatih E. Role of ursodeoxycholic acid in prevention of methotrexate-induced liver toxicity. *Dig Dis Sci* 2008; 53:1071. doi:10.1007/s10620-007-9949-3.
35. Azim EL and Amira OA. Antioxidant effect of olive leaf extract on methotrexate- induced hepatic injury in rats. *Canad J Clin Nutr*, 2014; 10(14206) :01-08.
36. Ghaffar FR Elaimy IA and Khaled AE. Protective and modulatory effects of curcumin and L-carnitine against methotrexate-induced oxidative stress in albino rats. *Res J Pharma Biol Chemi Sci* 2013; 4: 744–754.
37. Youssef GA. Role of *Ginseng* as hepatoprotective, antioxidant and anti - inflammatory against methotrexate induced liver injury in rats. *The Egyptian Journal of Hospital Medicine* 2016; 62:105–108. doi: 10.12816/0021419..
38. Aydin B. Quercetin prevents methotrexate-induced hepatotoxicity without interfering methotrexate metabolizing enzymes in liver of mice. *J App Biol Sci* 2011; 5 (2): 75-80.
39. AliM Mruthunjaya K Nandini C and Nabeel K . Chemoprotective effect of Noni (*Morinda citrifolia* L.) fruit juice against cisplatin -induced nephrotoxicity. *Int J Pharmacy Pharmaceutical Sci* 2016; 8(10): 08–13.
40. Reddy YV Reddy PS Shivalingam MR Rao BA and Sindhura K. Cisplatin and carboplatin induced changes in oxidative enzyme activity levels in albino rat's liver. *Int J Pharm Biomed Res* 2010; 1: 94-97.
41. Akanji MA and Nlumanze SE. Alkaline phosphatase activities following repeated suramin administration in some rat tissues in relation to their functions. *Pharmacol Toxicol* 1987; 61(3): 182-183.
42. Ghosh DE Syed BF Elina M Monalisa D and Debasish B. Protective effect of aqueous leaf extract of *Murraya koenigi* against lead induced oxidative stress in rat liver, heart and kidney: a dose response study. *Asian J Pharm Clin Res* 2012; 5: 54-58.
43. Bhavani R Nandhini S Rojalakshmi B Shobana R and Rajeshkumar S. Effect of Noni (*Morinda citrifolia*) extract on treatment of ethylene glycol and ammonium chloride induced kidney disease. *Int J Pharma Sci Res* 2014; 5(6):249-256.
44. Saadia SA. The role of antioxidant (vit-A and glutamine) in ameliorating methotrexate induced hepatic toxicity in rats. *Kufa J Vet Medical Sci* 2012; 3(1):113-123.
45. Gupta RK Ayan B Suajta P Chandresh S and Neeta S. Induction of mitochondrial-mediated apoptosis by *Morinda Citrifolia* (Noni) in human cervical cancer cells. *Asian Pac J Cancer* 2013; 14(1):237-242.
46. Sail AI Mahdawi FA Makarim Q Lama A and Jalabi SM. Protective effect of vitamin A against oxidative stress caused by methotrexate. *Iraqi J Sci* 2013; 54(3):585-589.
47. Wang MY and Su C. Cancer preventive effect of *Morinda citrifolia* (Noni). *Annals of the New York Academy Sciences* 2001; 952:161–168.
48. Cakir T Ozkan E Dulundu E Topaloglu U Sehirlil AO Sener EFand Sener G. Caffeic acid phenethyl ester (CAPE) prevents methotrexate-induced hepatorenal oxidative injury in rats. *J Pharmacy Pharmacol* 2011; 63(12): 1566–1571.
49. Genestra M. Oxyl radicals, redox- sensitive signalling cascades and antioxidants. *Cell Signal* 2007; 19:1807-1819.
50. Viswa KK Premila A and Bina I. Alteration in antioxidant defence mechanisms in the small intestines of methotrexate treated rat may contribute to its gastrointestinal toxicity. *Cancer Therapy* 2007;5:501–510.
51. Seven A Guzel S Seymen O and Civelek S. Effects of vitamin E supplementation on oxidative stress in strptozotocin induced diabetic rats. *Investigation of liver and plasma. Yonsei Med J* 2004; 45:703-710.
52. Bardrul AM Sarowar HM Chowdhry NS Ehsanul HM Haque EM and Anwarul I. *In vitro* and *in vivo* antioxidant and toxicity evaluation of different fractions of *Oxalis Corniculata* Linn. *J Pharmacol Toxicol* 2011; 6: 337-348.
53. Bhadauria M Nirala, KS and Shukla S. Multiple treatment of *Propolis* extract ameliorates carbon tetrachloride induced liver injury in rats. *Fd Chem Toxicol* 2008; 46: 2703-2712.
54. Cetin A Kaynar L Eser B Karada C Saraymen B and Ozturk A. Beneficial effects of *Propolis* on methotrexate-induced liver injury in rats. *Acta Oncologica Turcica* 2011; 44:18–23.

55. Ozogul B Kisaoglu A Turin MI Altuner D Sener E and Cetin N. The effect of mirtazapine on methotrexate-induced toxicity in rat liver. *Science Asia* 2013; 39:356-362.
56. Vijayakumari B Yadav H and Parimaladevi R. Enzymatic antioxidant of *Ficus carica*, *Emblica Officinalis*, *Cephalandra Indica* and *Terminalia chebula*. *Int J Pharma Biosci* 2012; 3: 426-430.
57. Wong YH and Abdul KH. Induction of mitochondria mediated apoptosis in Ca Ski human cervical cancer cells triggered by mollic acid arabinoside isolated from *Leea indica*. *Evid Based Complement Alternat Med* 2012. 6847. doi: 10.1155/2012/684740.
58. Cuzzocrea S Mazzon E Costantino G Serraino I De SA and Caputi AP. Effects of N-acetylcysteine in a rat model of ischemia and reperfusion injury. *Cardiovasc. Res* 2000;47: 537-548.
59. Chelikani P Fita I and Loewen PC. Diversity of structures and properties among catalases. *Cell Mol Life Sci* 2004; 61:192-208.
60. Pattabiraman K and Muthukumaran P. Antidiabetic and antioxidant activity of *Morinda tinctoria roxb* fruits extract in streptozotocin-induced diabetic rats. *Asian J Pharm Tech* 2011; 1(2):34-39.